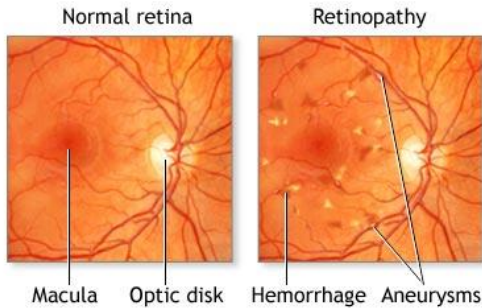


Unit B4, The Sands Complex
P.O. Box 2434, Bay Rd. Basseterre, St Kitts W.I
1(869)465-0152; Cell: 1(869)762-1954; Fax 1(869) 465-0153
E-MAIL: drnisbett@sknvision.com; WEB: <http://www.sknvision.com>

Diabetic Retinopathy



High blood-sugar levels from diabetes can damage blood vessels in your retina, the layer of nerve tissue at the back of your eye. This damage is called diabetic retinopathy. Early diagnosis and treatment can prevent vision loss, and it's important to maintain control of your blood sugar if you have diabetes.

What are the risk factors for diabetic retinopathy?

- You have type 1 diabetes
- You have type 2 diabetes
- You do not follow a strict diet
- You do not control your blood sugar levels

Reducing your risk

To reduce your risk or manage the disease, everyone with type 2 diabetes must be seen at least yearly by an ophthalmologist, Dr Nisbett, from the time of diabetes diagnosis. If you have been diagnosed with type 1 diabetes, you should see an ophthalmologist yearly beginning five years after the time of diabetes diagnosis.

Maintaining strict control of your blood sugar and following a strict diet are essential to preventing diabetic retinopathy in patients with diabetes.

Regular medical eye exams can help prevent unnecessary vision loss. The American Academy of Ophthalmology now recommends that adults with no signs or risk factors for eye disease get a baseline eye disease screening at age 40—the time when early signs of disease and changes in vision may start to occur. Based on the results of the initial screening, Dr Nisbett will prescribe the necessary intervals for follow-up exams.

Symptoms and Diagnosis

Often there are no symptoms in the early stages of diabetic retinopathy. Don't wait for symptoms to have a comprehensive eye exam.

If you suddenly see a few specks or spots floating in your vision, this may indicate proliferative diabetic retinopathy, the growth of abnormal new blood vessels on your retina and optic nerve.

Blurred vision may occur when the macula – the small area at the center of the retina – swells from fluid leaking from retinal blood vessels. Rapid changes in blood sugar can cause temporary blurring of vision in both eyes even if retinopathy is not present.

You should have your eyes checked promptly if you experience changes in your vision that last more than a few days and are not associated with a change in blood sugar.

A medical eye examination is the best way to detect changes inside your eye. An ophthalmologist, Eye M.D., can often diagnose and treat serious retinopathy before you are aware of any vision problems. The doctor dilates your pupil and looks inside of the eye with special instruments.

People with diabetes should schedule examinations at least once a year. More frequent medical exams may be necessary after a diagnosis of diabetic retinopathy.

- The gold standard for diagnosis is dilated retinal photography with accompanying ophthalmoscopy if the retinal photographs are of inadequate quality (e.g., cataract clouding view). If DR is present, it is classified as above.
- Further investigation such as optical coherence tomography (a sort of visual biopsy obtained in a similar fashion to an ultrasound scan but using light waves) or fluorescein angiography may be required to refine the diagnosis further and to guide management.

Investigations

- Fundus photography and examination are sufficient for most patients.
- However, optical coherence tomography is playing an increasingly important role in assessing the presence of macular edema (and then recording its progression over several visits) and fluorescein angiography may be helpful where CSMO is present (to guide laser treatment) and where the vision is unexpectedly poor (to assess for macular ischemia).

Management

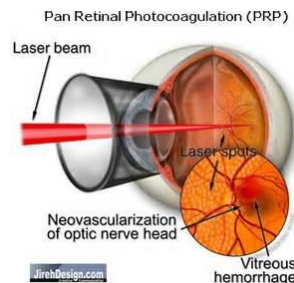
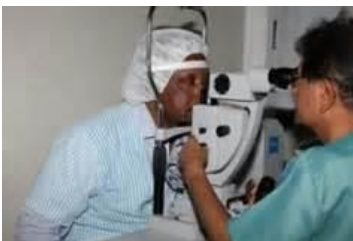Primary prevention

- Glycemic control:
 - Optimal glycemic control (usually aiming to bring HbA1c levels to <7%, ideally around 6.5%) is associated with improved long-term outcomes and delayed progression of retinopathy.
 - However, in some cases, particularly with pre-proliferative and proliferative retinopathy, intensive glycemic control (e.g., HbA1c at 6.0%) can initially bring on a decompensation and worsening of symptoms and signs and is also associated with increased mortality.
 - Pioglitazone should be avoided in the presence of macula edema.
- If you have diabetes and you are 29 years old or younger, Dr Nisbett within five years of your diagnosis. If you are 30 years old or older, see n Dr Nisbett within a few months of your diagnosis.
- Pregnant women with diabetes should schedule an appointment in the first trimester, because retinopathy can progress quickly during pregnancy.

Ophthalmic Treatment

Most patients with DR do not need treatment. If they do, there are several treatment modalities available:

Laser treatment:



- This has been the mainstay of treatment for a period of 25 years: the aim is to induce regression of new blood vessels and reduce central macular thickening. It is thought that the procedure works by reducing the release of vasoproliferative mediators by hypoxic retinal vessels and allowing easier direct diffusion of oxygen from the choroid blood supply.
- Laser treatment can arrest the progression of DR but is unlikely to restore any lost vision.
- Treatment can be targeted on to specific areas (focal treatment) or delivered over the entire periphery of the retina (pan retinal photocoagulation (PRP)) where 1,200-1,600 burns may be placed on the retina over 2-3 sessions. The choice depends on the nature of the DR: macular edema is treated with focal laser burns whereas retinopathy is more amenable to PRP. If there is both retinopathy and maculopathy, macular edema is often treated first and separately before treatment with PRP.
- Laser treatment is carried out in a laser treatment clinic on an outpatient basis. At a later date, the areas of laser treatment are easily identifiable as well demarcated pale spots with distinct dark brown centers - this can be helpful if the patient cannot remember if they have previously had treatment!
- The decision as to whether to carry out laser treatment is not always clear-cut (e.g., asymptomatic patients with CSMO but no visual loss).

Intravitreal steroids:

- A large trial has demonstrated that intravitreal steroids were initially more effective than treatment with laser photocoagulation but that two years' post-treatment, eyes treated with laser actually had better visual acuity and less maculopathy.
- Intravitreal triamcinolone appears to reduce CSMO and improve visual acuity in more advanced cases. It may be used as primary or adjunctive therapy. The effect is maximal after a week but may last up to six months.
- The mechanism of action of corticosteroids is not fully understood.
- This treatment modality is associated with complications (see 'Complications', below).
- Fluocinolone acetonide:
 - Fluocinolone acetonide intravitreal implant is a corticosteroid that has anti-inflammatory and anti-vascular endothelial growth factor properties.
 - NICE guidance currently states that fluocinolone acetonide intravitreal implant is not recommended for the treatment of chronic diabetic macular edema considered insufficiently responsive to available therapies.

Anti-vascular endothelial growth factor treatments:

- In recent trials, anti-vascular endothelial growth factor drugs have shown a definite but small benefit compared to other current therapeutic options for the treatment of diabetic macular edema.
- Pegaptanib, bevacizumab and ranibizumab have all been investigated with promising results.
- Currently, both price and the frequency of attendance required (both for the injections and the follow-up) limit the use of these treatments in clinical practice. Ranibizumab is currently not recommended by the National Institute for Health and Clinical Excellence (NICE) for the treatment of visual impairment due to diabetic macular edema.

Surgery:

- A vitrectomy (removal of the vitreous) may be required following an intravitreal bleed in proliferative DR.
- Not only does it physically remove the blood to allow vision through a clear medium, but any retinal detachment can also be repaired. Intra-operative PRP reduces the stimulus for neovascularization.

Complications

The main complication of diabetic retinopathy is visual loss secondary to:

- Macular edema.
- Macular ischaemia.
- Vitreous haemorrhage.
- Tractional retinal detachment.

However, treatment modalities are also associated with risks.

- **Complications of focal/grid photocoagulation:**
 - Impaired central vision.
 - Paracentral scotoma.

- Choroidal neovascularization.
- Epiretinal membrane formation.
- Worsening of macular edema in a minority.
- **Complications of pan retinal photocoagulation:**
 - Constriction of visual field.
 - Nocturnal diminution of vision/blindness.
 - Burns affecting the fovea centralis.
 - Worsening macular edema.
 - Serous and/or choroidal detachment.
 - Ocular pain.
 - Anterior chamber adverse effects -, e.g. burns affecting the cornea or lens.
- **Complications of intravitreal steroids and triamcinolone:**
 - Cataract formation.
 - Raised intraocular pressure.

Prognosis

- Background retinopathy will eventually progress to the more severe forms in the majority of individuals. If left untreated: 50% of those with proliferative DR will lose their sight within 2 years and 90% risk losing any useful vision after 10 years.
- Patients who undergo treatment have their risk of moderate visual loss reduced from 30% to 15% over the subsequent 3 years. Those who have pan retinal photocoagulation have their risk of severe visual loss reduced by 50%, compared with untreated individuals with a similar severity of disease.

Other eye conditions associated with diabetes

Cataracts

- A classic diabetic cataract is rare. The cataract is manifest as snowflake opacities occurring in the young person with diabetes. It may resolve spontaneously, or mature.
- More commonly, an age-related cataract is precipitated in the diabetic patient, to form earlier than it would have done otherwise.

Eye conditions less commonly associated with diabetes

- Premature presbyopia and other refractive errors due to the reduced pliability of the lens secondary to an altered metabolism.
- Rubeosis iridis describes the process when severe ischemia causes neovascularization to such an extent that the vessels grow forward and over the iris. The vessels may be seen as large individual entities or else give the iris a generally red appearance. If they block the peripheral trabecular meshwork (through which most of the aqueous drains - see separate article Primary Open Angle Glaucoma) on the way, they may precipitate acute glaucoma, which needs urgent treatment.
- Occasionally, ocular motor nerve palsies occur, presumably due to the damage of the microvascular supply of these cranial nerves. Patients should be presumed to have an intracranial mass until proven otherwise via imaging. If it is truly a palsy related to diabetic microvasculopathy, it often resolves over a period of months but orthoptic input may be needed.
- Other eye conditions more commonly found in diabetics include dry eyes, corneal abrasions, anterior uveitis, ocular ischemic syndrome, papillitis and orbital infections.
- Corneal abnormalities may also be found in these patient groups. ^[5]
- Asteroid hyalosis is a condition characterized by little white flecks seen in the vitreous. It can occur for a number of reasons and is usually asymptomatic. Unless very severe and affecting vision, it is left alone.